

Mario Novak*

BIOARCHAEOLOGICAL ANALYSIS OF THE HUMAN SKELETAL REMAINS FROM TUMULUS NO. 2 ON PLANINICA HILL, OBŠ. TUZI, MONTENEGRO

ABSTRACT

Novak M. Bioarchaeological analysis of the human skeletal remains from tumulus No. 2 on Planinica Hill, obš. Tuzi, Montenegro. *Sprawozdania Archeologiczne* 65, 435–438.

Human remains from the sarcophagus in the Tumulus II on the Planinica Hill have been analysed in the laboratory of the Department of Archaeology of the Croatian Academy of Sciences and Arts in Zagreb. Due to the severe fragmentation and post-mortem damage of the whole sample it was not possible to re-individualise each skeleton; instead, a minimum number of 7 individuals (MNI) buried in the tumulus were assessed. Analysis of the bones belonging to the adult individuals showed that they fell between the ages of 16 and 20 years old, for the youngest, while the oldest individual was probably between 50 and 60 years old.

Key words: the Bronze Age, Montenegro, stone tumuli, anthropological analyses

Received: 1.05.2013; Revised: 21.06.2013; Accepted: 29.07.2013

Human skeletal remains from archaeological sites are an important resource for understanding the living conditions of past populations. When the archaeological artefacts are inconclusive and written sources are scarce or non-existent bioarchaeological analyses of human osteological and dental remains are often the only means to obtain a better insight into the way of living of our ancestors.

The bioarchaeological study of human skeletal and dental remains from tumulus 2 was carried out in the laboratory of the Department of Archaeology of the Croatian Academy of Sciences and Arts in Zagreb. Unfortunately, due to the severe fragmentation and post-

* Department of Archaeology, Croatian Academy of Sciences and Arts, Ante Kovačića 5, 10 000 Zagreb, Croatia; mnovak@hazu.hr

mortem damage of the whole sample it was not possible to re-individualise each skeleton; instead, a minimum number of individuals (MNI) buried in the tumulus was assessed. The minimum number of individuals in any bone assemblage of bones is the minimum numbers of individuals necessary to account for all the elements in the assemblage (White, Folkens 2005). Although the re-individualisation was not possible an estimation of sex and the age at death of the recovered skeletal remains were given in as many cases as possible using methods described in Buikstra and Ubelaker (1994).

As already mentioned, the preserved bones are severely fragmented with pronounced post-mortem damage (weathering) (Fig. 1), varying between white and yellow in colour. Differences in colour between the various bone fragments were caused by exposure to the sun and external influences. No traces of incineration were recorded.

In the analysed sample fragments of cranium and long bones (mostly diaphyses) are most frequent, while smaller bones (fragments of ribs, vertebrae, phalanges) are rare. The minimum number of individuals buried in tumulus 1 is seven based on the presence of seven left and seven right temporal bones (Fig. 2). Due to the extreme fragmentation and post-mortem damage it was possible to estimate the sex of only four individuals (all males) based on four robust occipital bones with pronounced nuchal area. Based on several criteria (the chronology of dental development, the degree of abrasion of the occlusal surfaces of the teeth, the degree of ossification of the main bones, and the degree of obliteration of cranial sutures) it may be concluded that all the analysed bones belonged to adult individuals, i.e. the youngest individual was between 16 and 20 years old (Fig. 3), while the oldest individual was probably between 50 and 60 years old.

All skeletal remains were examined for the presence of pathological changes, considering that during the life of an individual the bones are in a dynamic state of growth and resorption, and react to stress and other influences from the environment (Işcan, Kennedy 1989; White 1991). A healed ante-mortem depressed fracture, oval-shaped, 14 x 9 mm in size, was recorded on the fragment of an occipital bone (Fig. 4). A slight, healed ectocranial porosity without vault thickening was recorded on six cranial fragments (parietal and occipital bones) (Fig. 5). Ectocranial porosity is a pathological change characterised by sieve-like pits on the outer vault of the skull (frontal bone, parietal bones, and occipital bone); it is an indicator of physiological stress associated with acute and severe malnutrition (Mann, Murphy 1990; Martin *et al.* 1985). Dental enamel hypoplasia (DEH) was observed on two maxillary canines (Fig 6.). DEH is a developmental defect consisting of irregularities in the enamel structure caused by interruptions or disturbances in its growth (Aufderheide, Rodríguez-Martin 1998). The most common cause of DEH is systemic physiological stress such as malnutrition, illness, infection or fever during tooth formation (Goodman, Rose 1990).

Dental analysis is a very important indicator in the determination of dietary habits, health condition, as well as the age of a person (Janković, Rajić-Šikanjić 2011). Accordingly, during the bioarchaeological analysis special attention was given to the alveo-dental re-



Fig. 1. Femoral bone fragment with extensive post-mortem damage

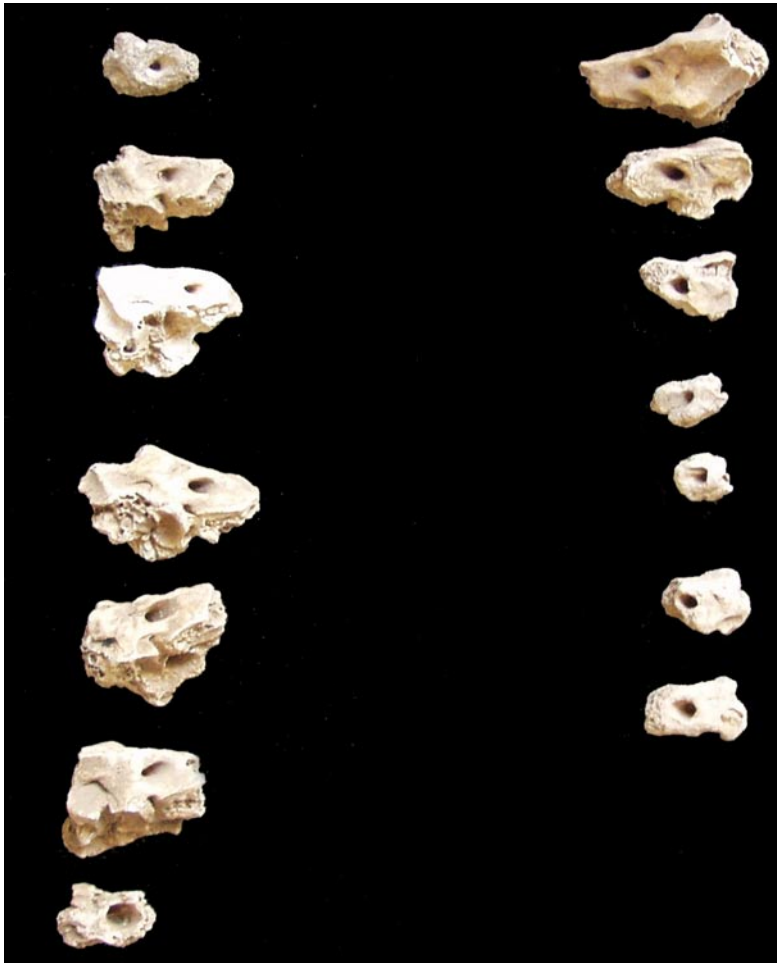

Fig. 2. Fragments of seven right and seven left temporal bones



Fig. 3. Unfused proximal femoral epiphysis belonging to a young adult individual (16–20 years)



Fig. 4. Fragment of the occipital bone with ante-mortem depressed fracture




Fig. 5. Fragment of the parietal bone with healed ectocranial porosity

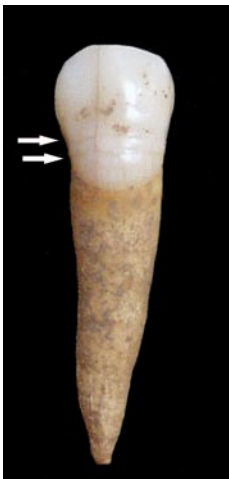

Fig. 6. Maxillary canine with dental enamel hypoplasia

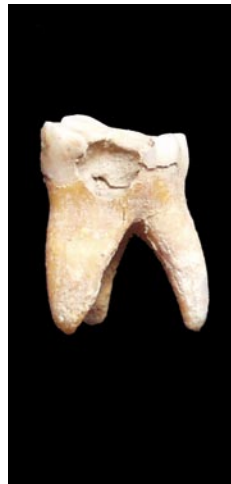

Fig. 7. Interproximal caries on the maxillary molar



Fig. 8. Severe abrasion of the occlusal surface of the maxillary premolar



Fig. 9. Fragment of an animal bone

mains. In total, 101 permanent teeth were analysed, and the vast majority were posterior teeth (molars and premolars). Carious lesions were observed in three teeth only (all molars) of which one is occlusal (the biting surface of the tooth) caries and two are interproximal (surface between the two teeth) caries (Fig. 7) – the prevalence of caries in the analysed sample is 3%. Beside teeth, 19 alveoli were studied, and ante-mortem tooth loss was recorded in only one alveolus. Most of the studied teeth are characterised by medium to severe abrasion (Fig. 8) thus suggesting two facts: 1) nutrition based on solid and less processed food that had strong abrasive effect on the occlusal surfaces of the teeth; 2) most of the individuals buried in tumulus 2 were over 40 years old at the time of death.

Besides human skeletal remains, one fragment of animal bone was present in the assemblage (Fig. 9).

Although the skeletal material from tumulus 2 is fragmented and heavily damaged the results of the bioarchaeological analysis presented in this paper revealed some new facts about the quality of life of the Bronze Age inhabitants of the Montenegrin Malesija. The presence of pathological changes such as ectocranial porosity and dental enamel hypoplasia strongly suggests that some of the analysed individuals were exposed to severe physiological stress (hunger, infectious diseases) during their lives, most probably during the childhood. The study of the dental remains indicates that the nutrition was based mostly on solid and unprocessed food that had a strong abrasive effect on the occlusal surfaces of the teeth, but it also suggests that most of the individuals buried in tumulus 2 were at the advanced stage of their life.

Considering that the bioarchaeological studies of the Bronze Age human skeletal remains from the Balkan region have been rarely published this research, along with previously published analyses, should represent only the initial step in creating a larger database of palaeodemographic and palaeopathological characteristics of the Bronze Age inhabitants of the Balkan peninsula. More comprehensive studies, especially molecular analyses, are in order if we want to broaden our knowledge of the Bronze Age inhabitants of the region.

References

- Aufderheide A.C. and Rodríguez-Martin C. 1998. *The Cambridge Encyclopedia of Human Paleopathology*. Cambridge.
- Buikstra J.E. and Ubelaker D. H. (eds.). 1994. *Standards for data collection from human skeletal remains* (= *Arkansas Archaeological Survey Research Series* 44). Fayetteville.
- Goodman A.H. and Rose J.C. 1990. Assessment of systemic physiological perturbations from dental enamel hypoplasias and associated histological structures. *Yearbook of Physical Anthropology* 33, 59–110.
- Işcan M.Y. and Kennedy K.A.R. (eds.). 1989. *Reconstruction of Life from the Skeleton*. New York.

- Janković I. and Rajić Šikanjić P. 2011. Analysis of human skeletal remains. In J. Balen (ed.), *Đakovo – Franjevac : kasno bakrenodobno naselje = Đakovo Franjevac: late eneolithic settlement*. Zagreb.
- Mann W.R. and Murphy P.S.1990. *Regional atlas of bone disease: a guide to pathologic and normal variation in the human skeleton*. Springfield.
- Martin D.L., Goodman A.H. and Armelagos G.J. 1985. Skeletal pathologies as indicators of quality and quantity of diet. In R.I. Gilbert and J.H. Mielke (eds.), *The analysis of Prehistoric diets*. Orlando.
- White T.D. 1991. *Human Osteology*. San Diego.
- White T.D. and Folkens P.A.2005. *The Human Bone Manual*. Amsterdam-Boston.